Dental caries
Lab

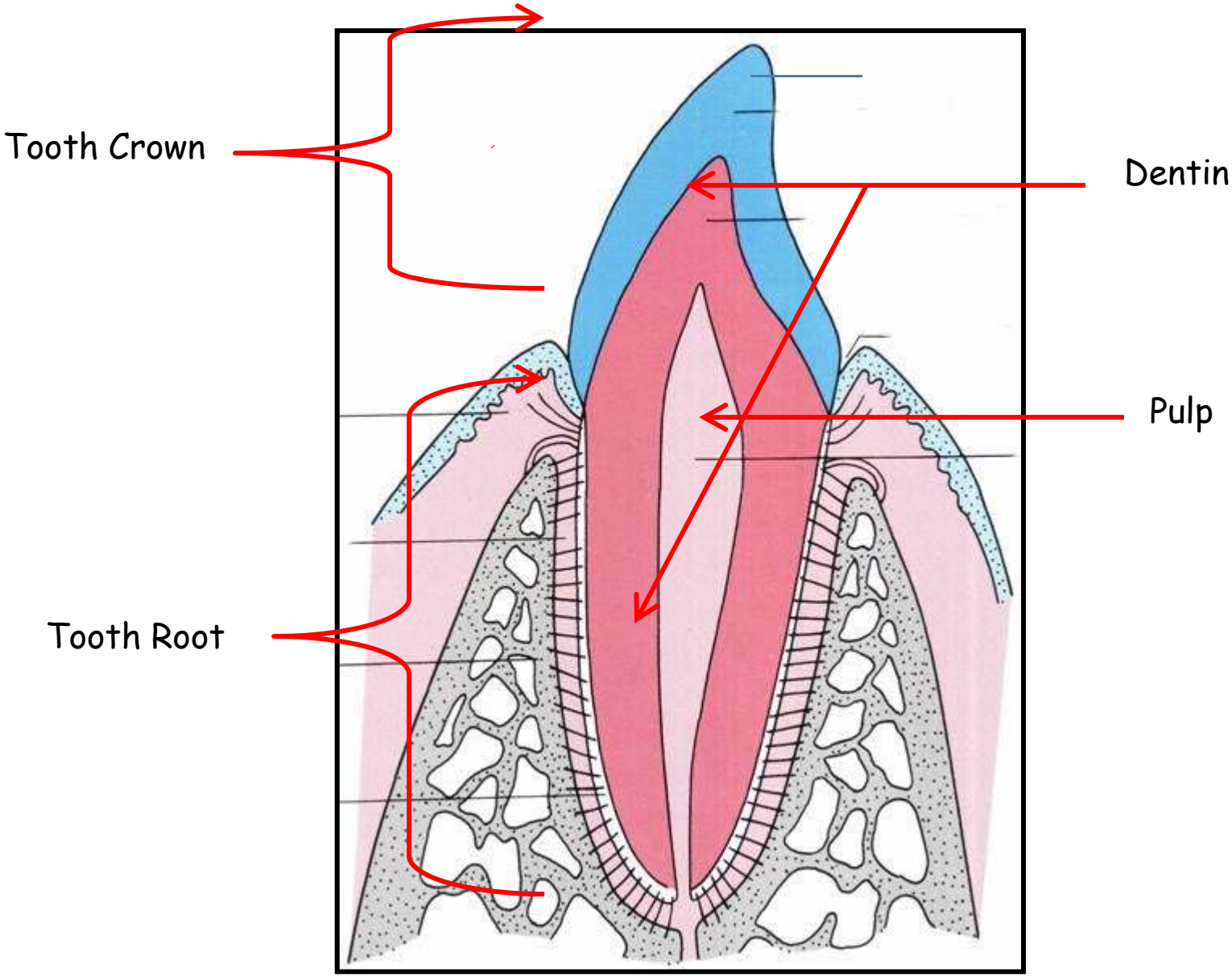
Tooth Crown
Dentin
Pulp
Tooth Root

Dental caries is defined as a progressive irreversible microbial disease of the hard(calcified) structure of the teeth , characterized by decalcification of the inorganic substance and destruction of the organic substance of the tooth to form a cavity.

Caries is one of the most common of all diseases and still a major cause of loss of teeth.

Loss of tooth substance may result from :

1. Bacterial Causes: as dental caries.

2. Non-bacterial Causes:

A. **Mechanical Causes:**

Attrition : by the action of opposing teeth. A small amount of attrition occurs with age, but accelerated wear may occur in bruxism .

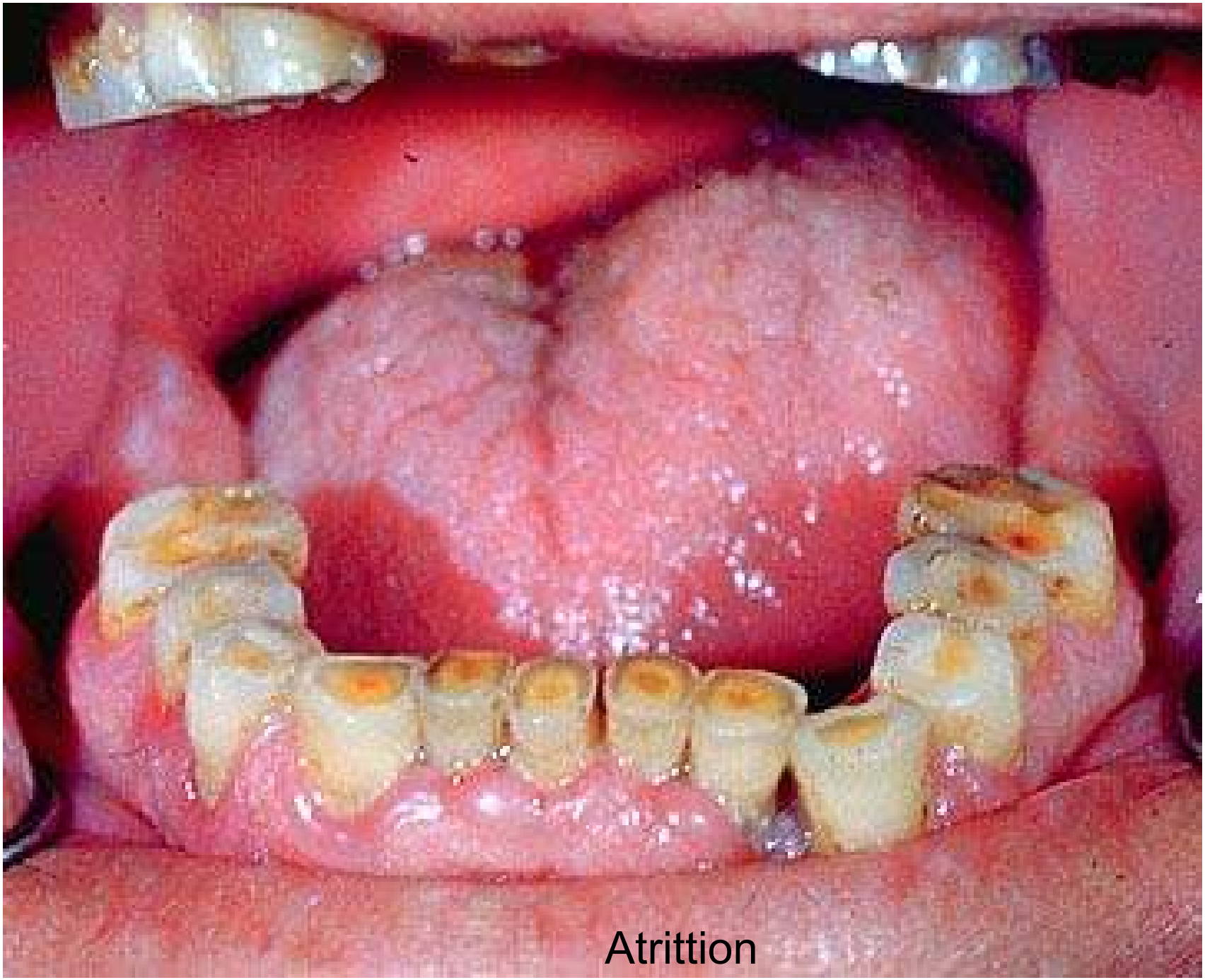
Atrittion

<u>Abrasion</u> : particularly at the gingival 1/3 by over vigorous brushing.

Abrasion

B. Chemical Causes:

Erosion : usually caused by repeated application of acid.

C. Pathological Resorption.

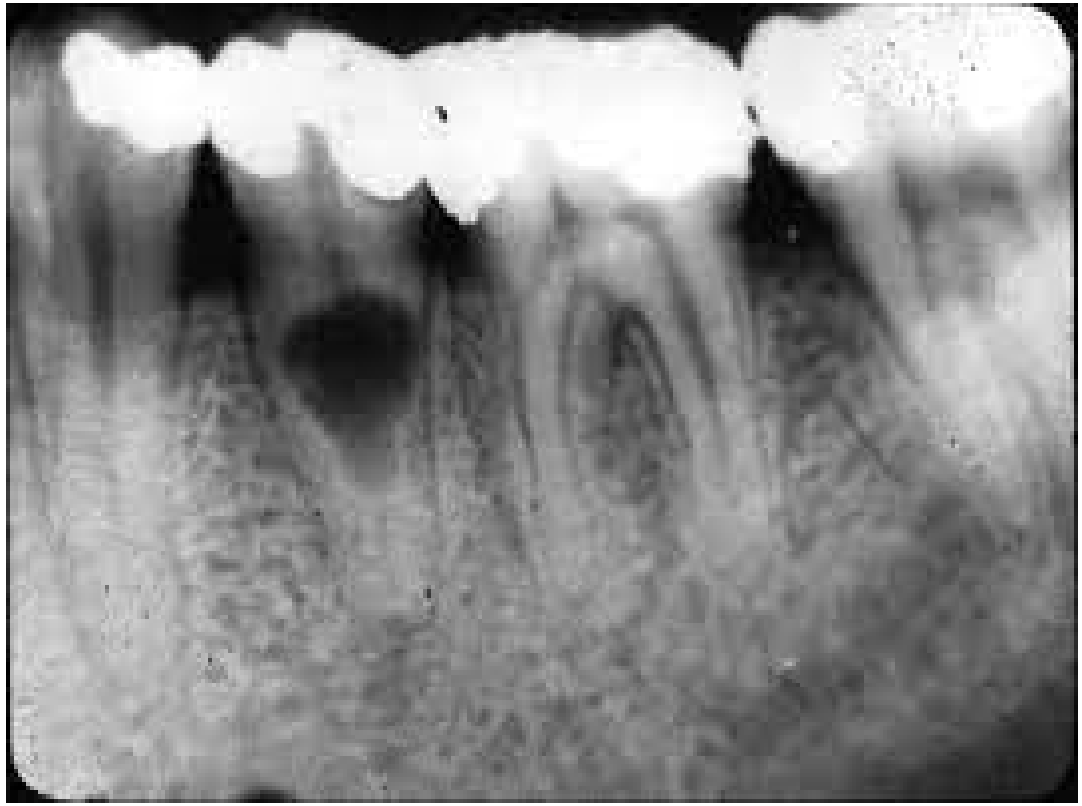

In general, the essential requirements for development of dental caries are:

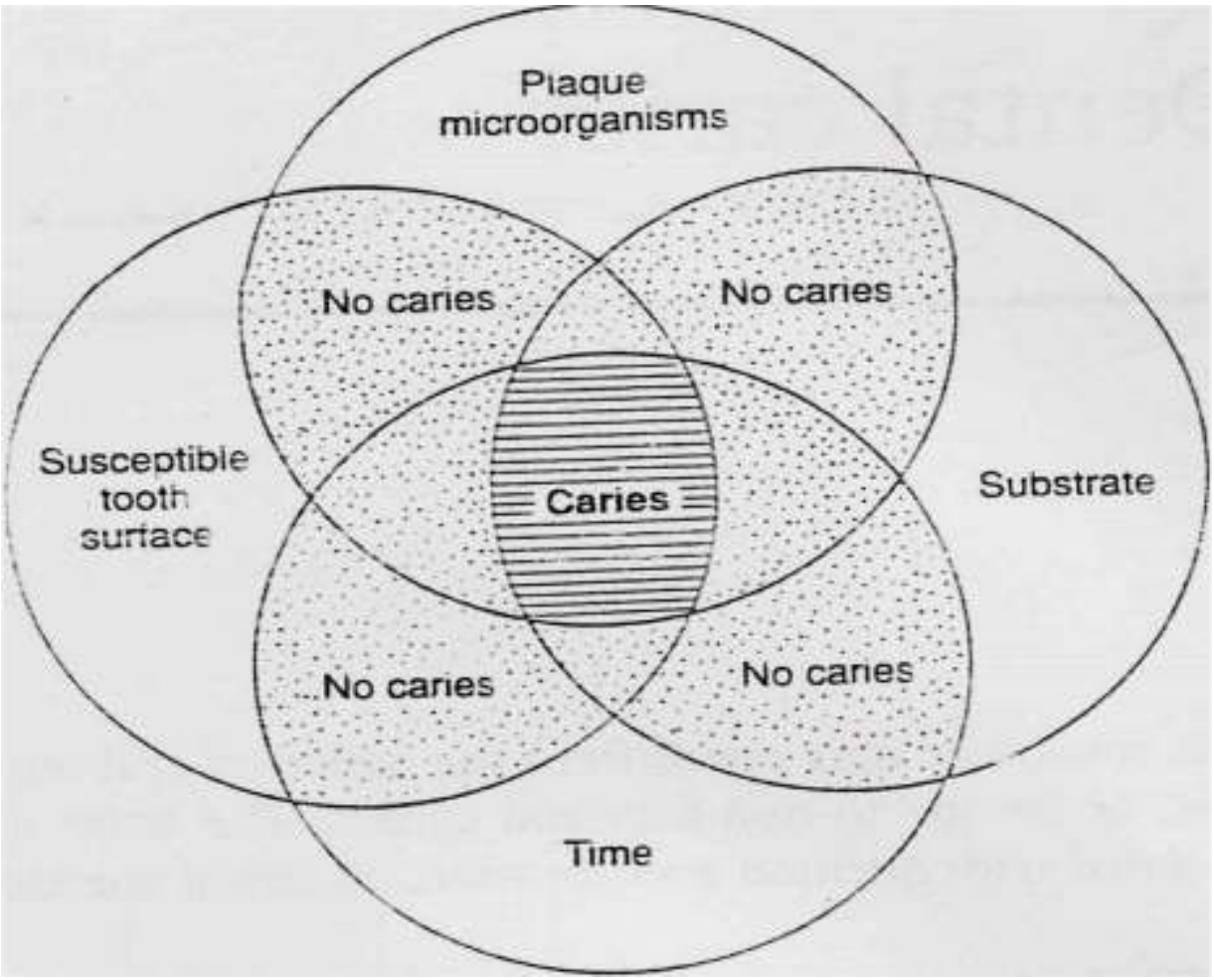

Clinical Classification of Dental Caries

It is classified either according to *site* of attack, or according to *rate* of attack.

A. *According to site of attack*

1. Pit and fissure caries.
2. Smooth surface caries.
3. Cemental or root caries.

Pit and fissure caries

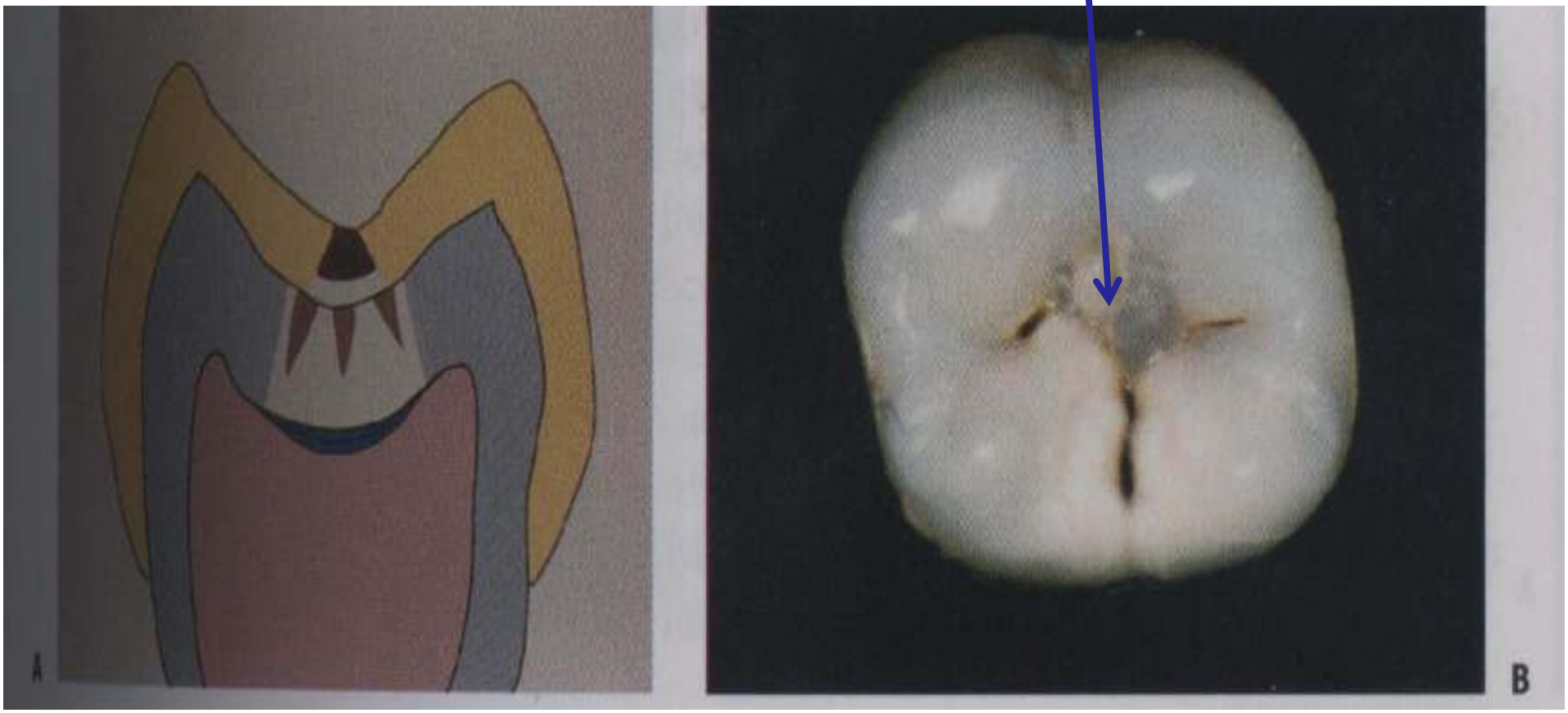

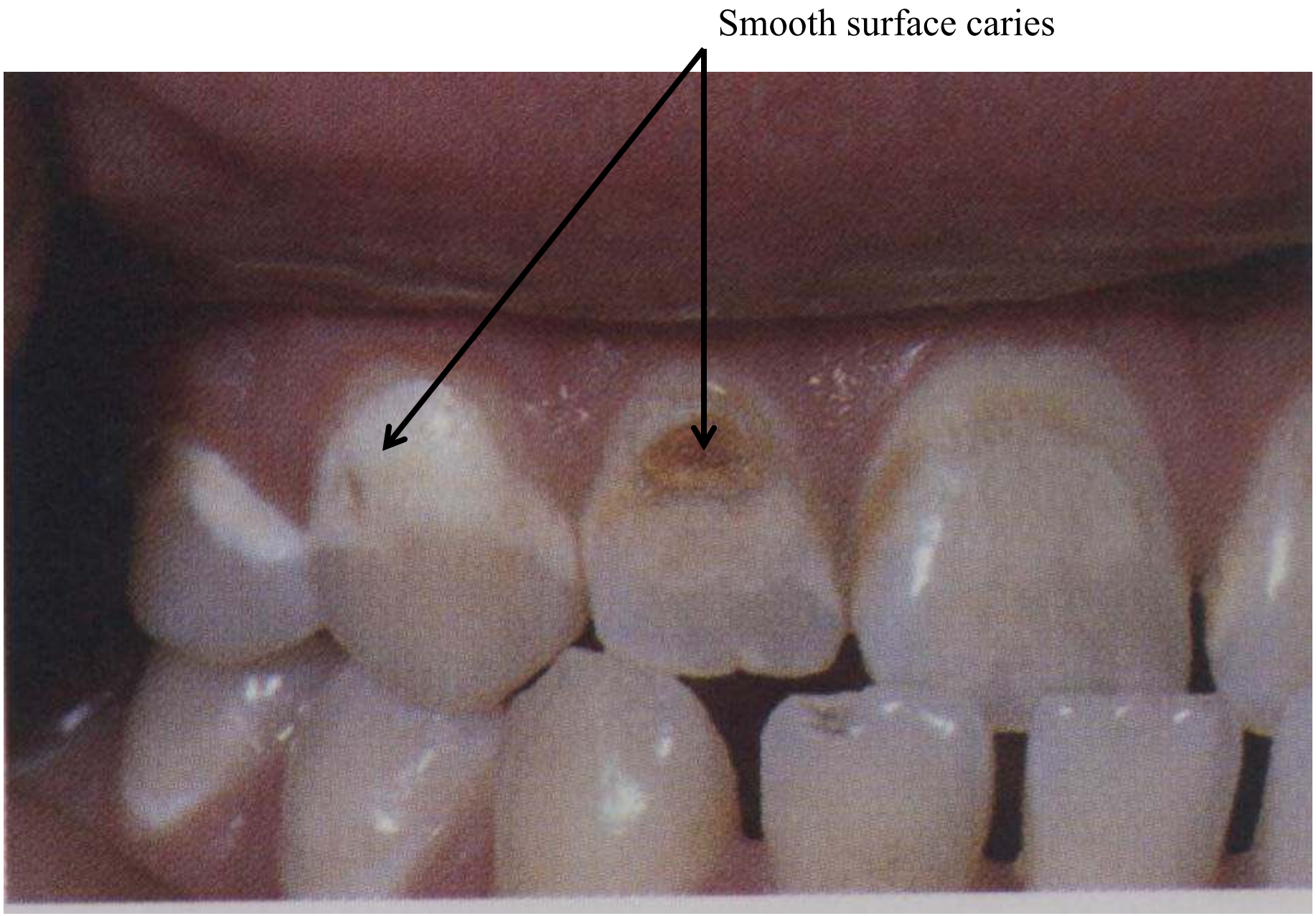
Smooth surface caries

Smooth surface caries

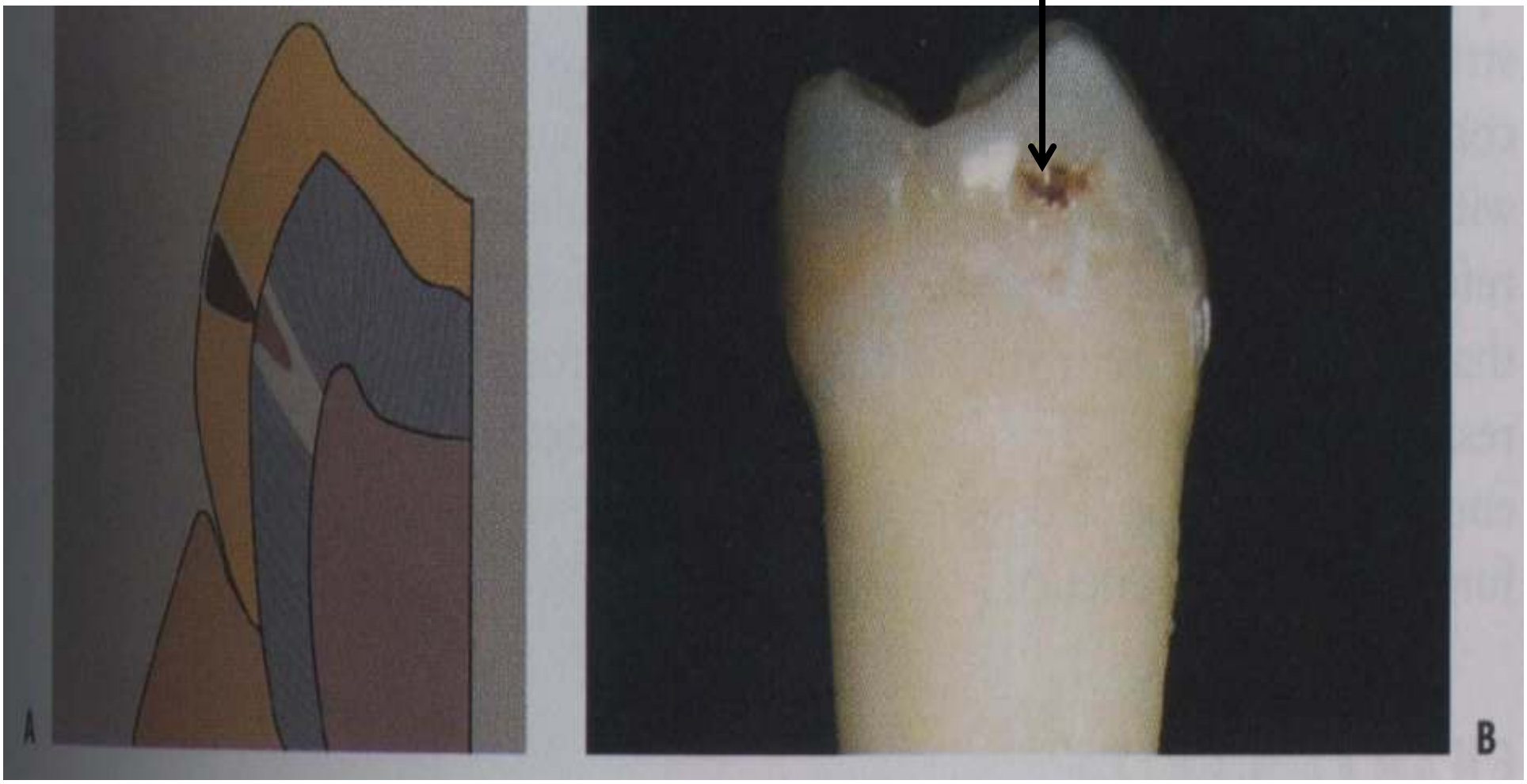

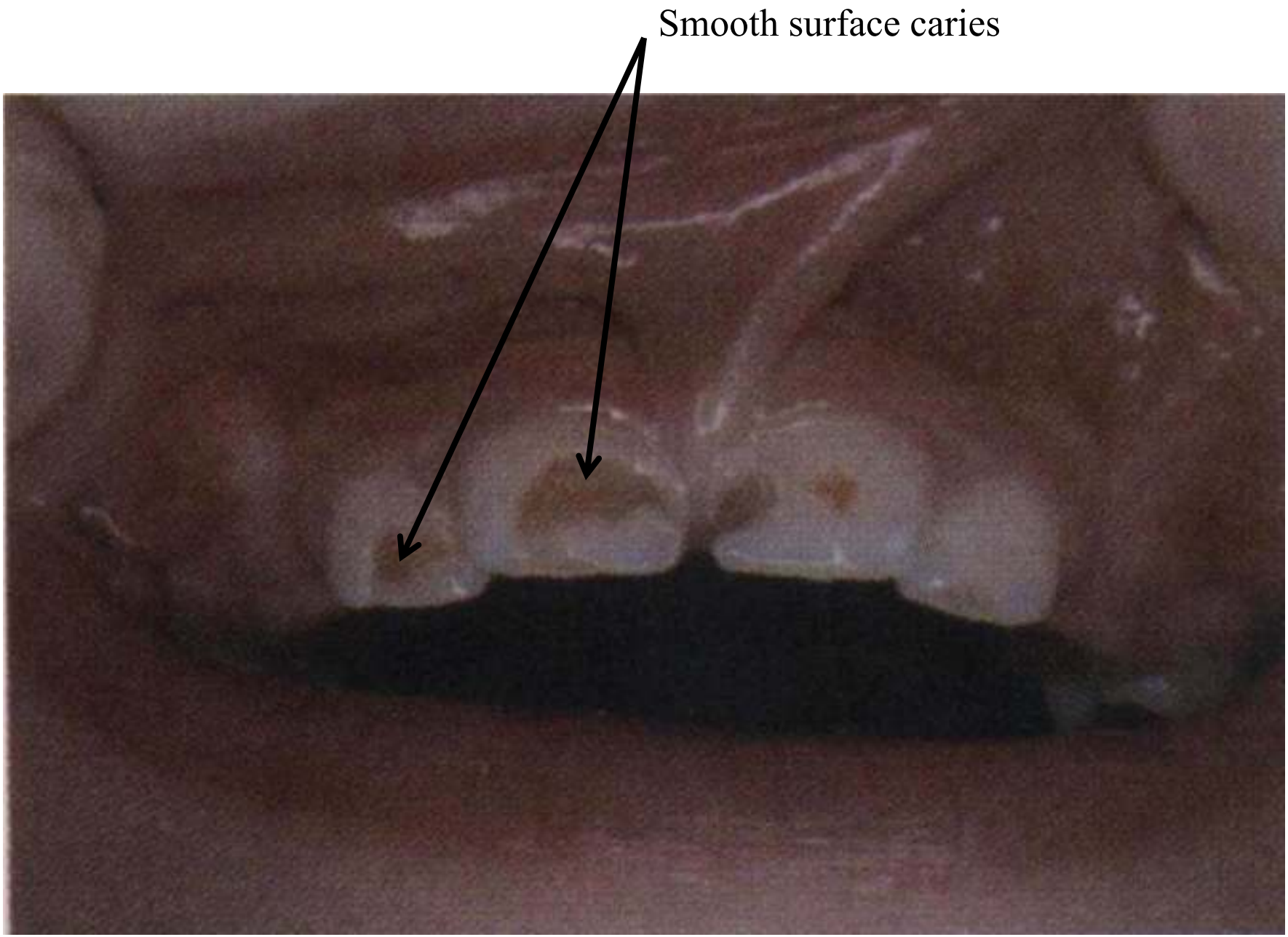
Smooth surface caries

Root caries

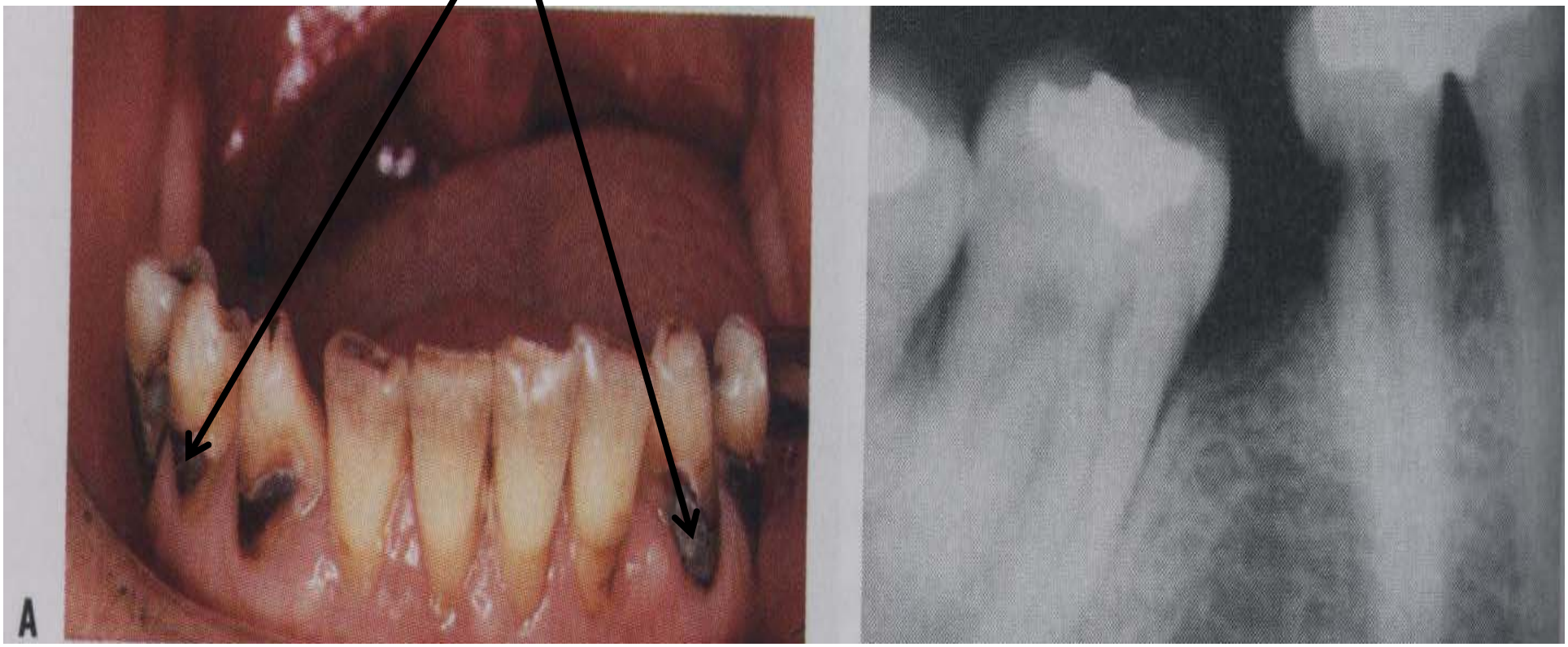

Recurrent caries

gure 17.3. Rampant caries associated with xerostomia.

- Nursing Bottle Caries

Histopathology of enamel caries

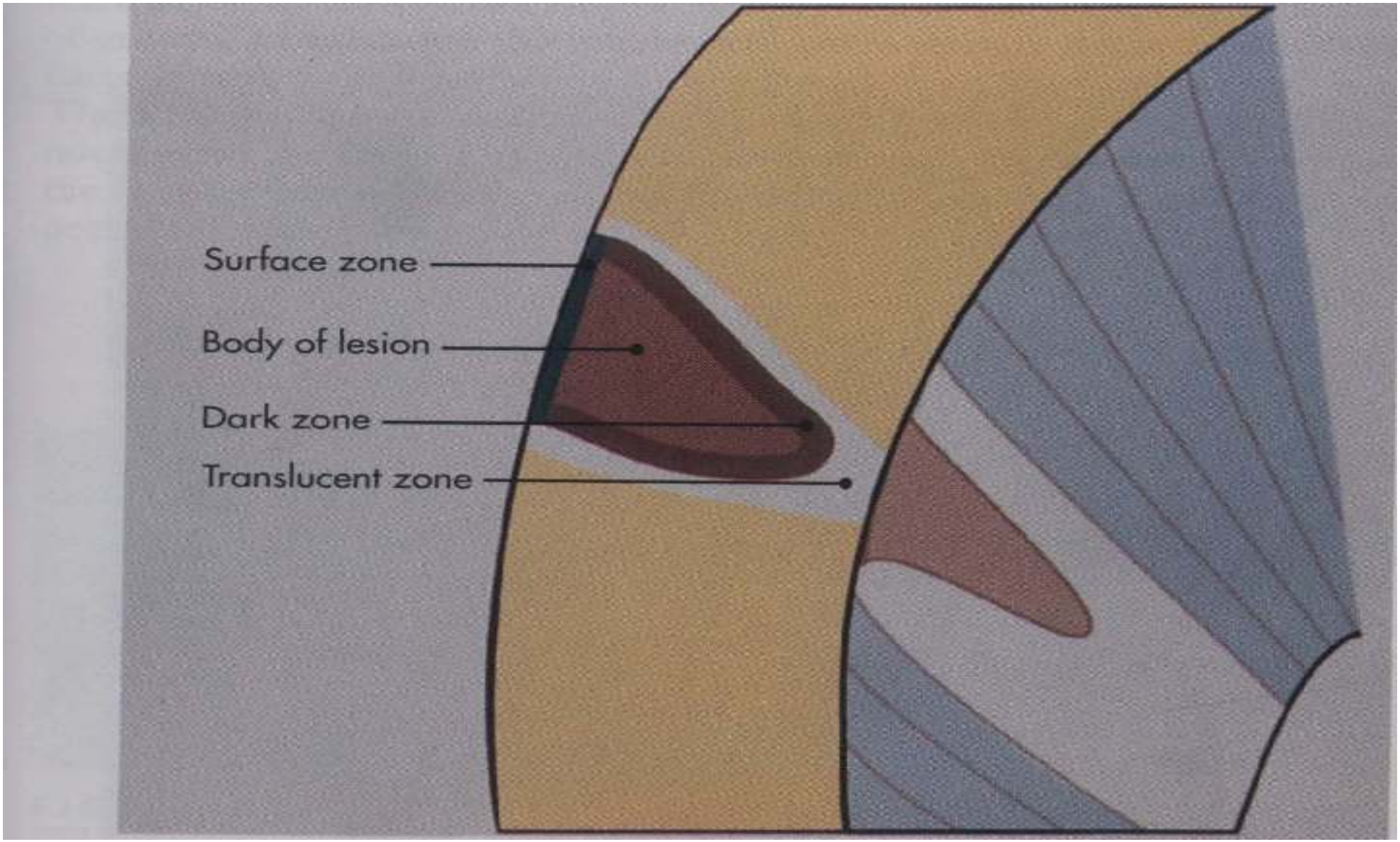



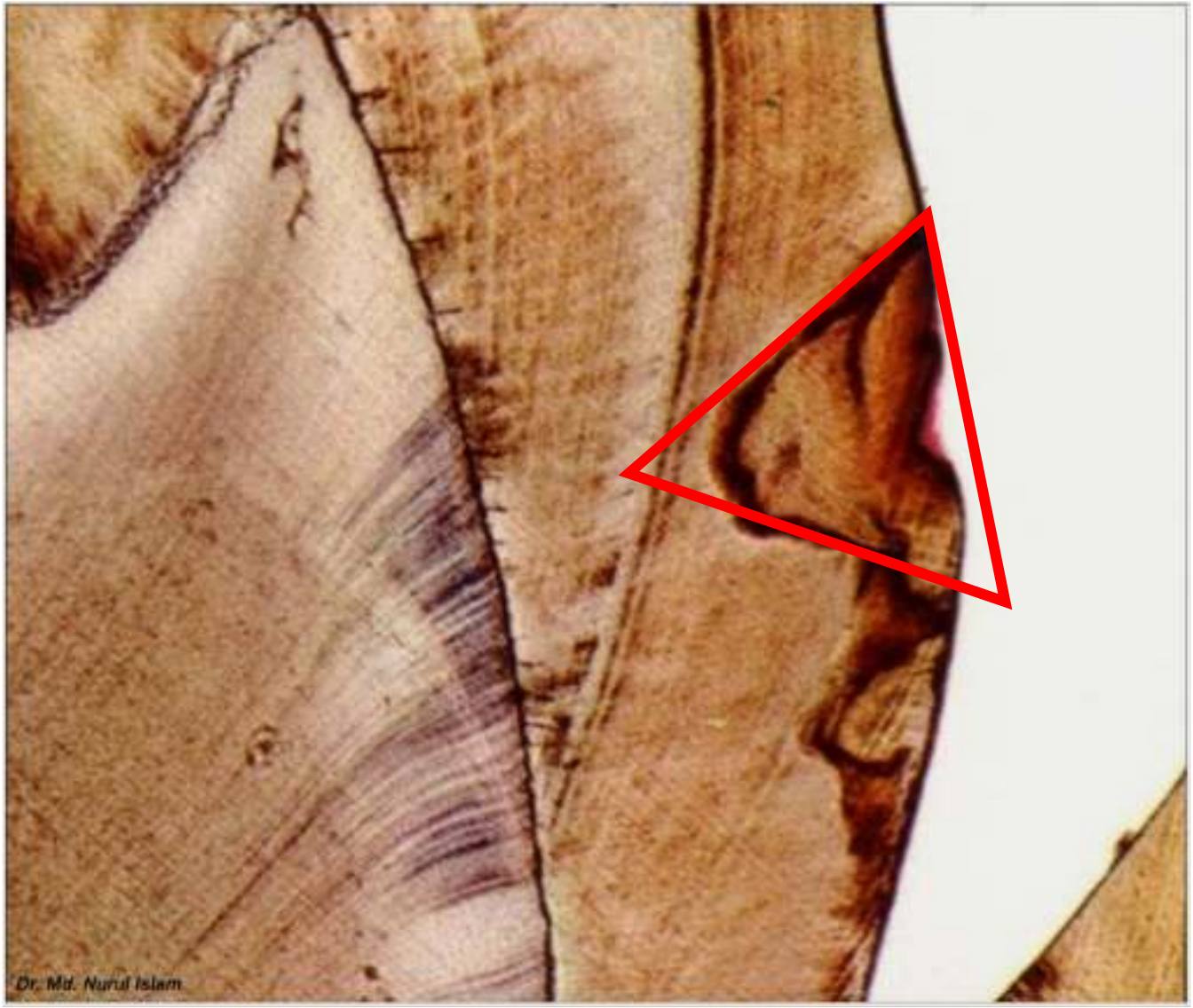
Dr. Md. Nurul Islam


B
SZ
Surface zone
Translucent zone
TZ
B
Body of lesion
DZ
Demineralization zone

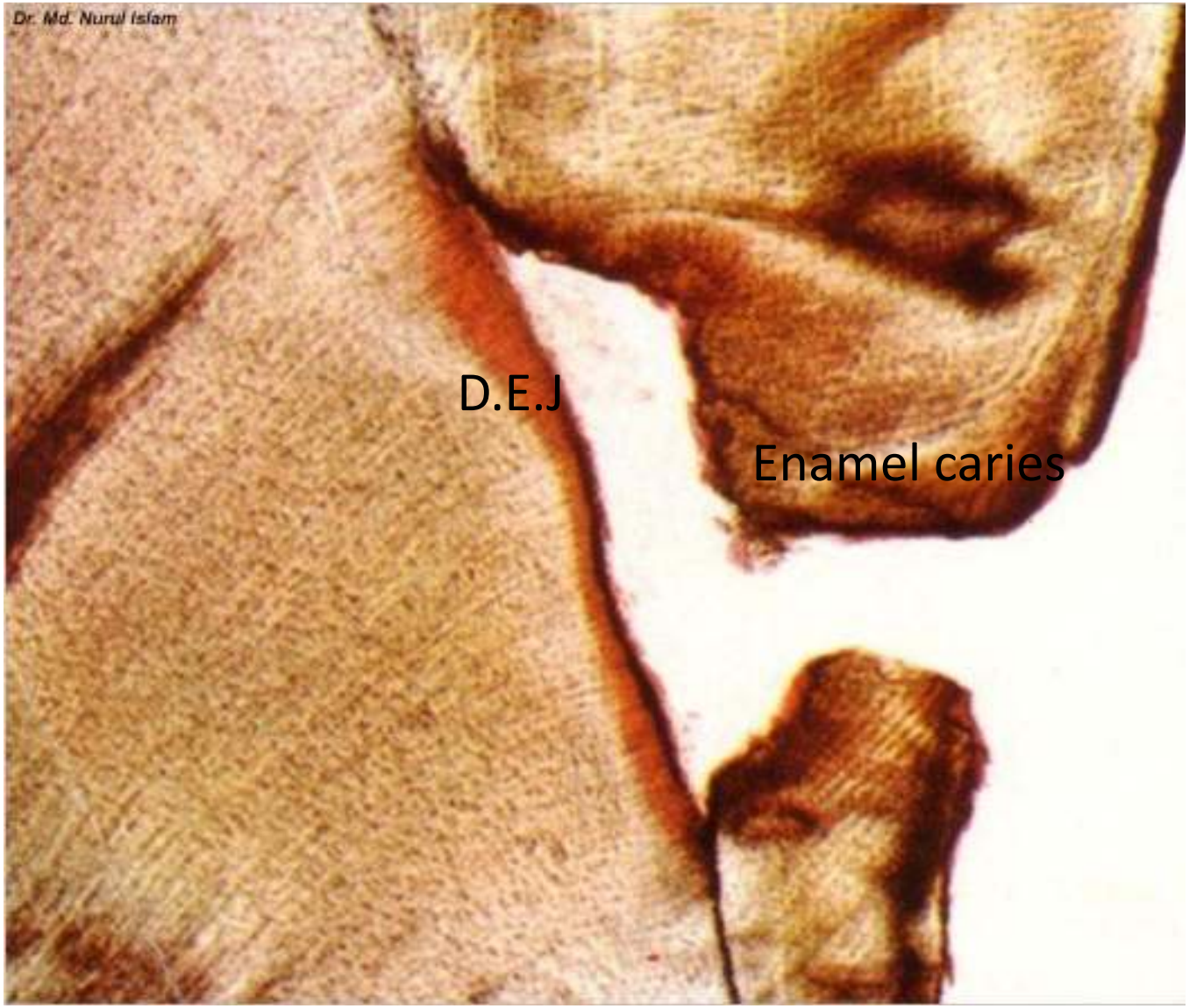
Dr. Md. Nurul Islam
D.E.J
Enamel caries

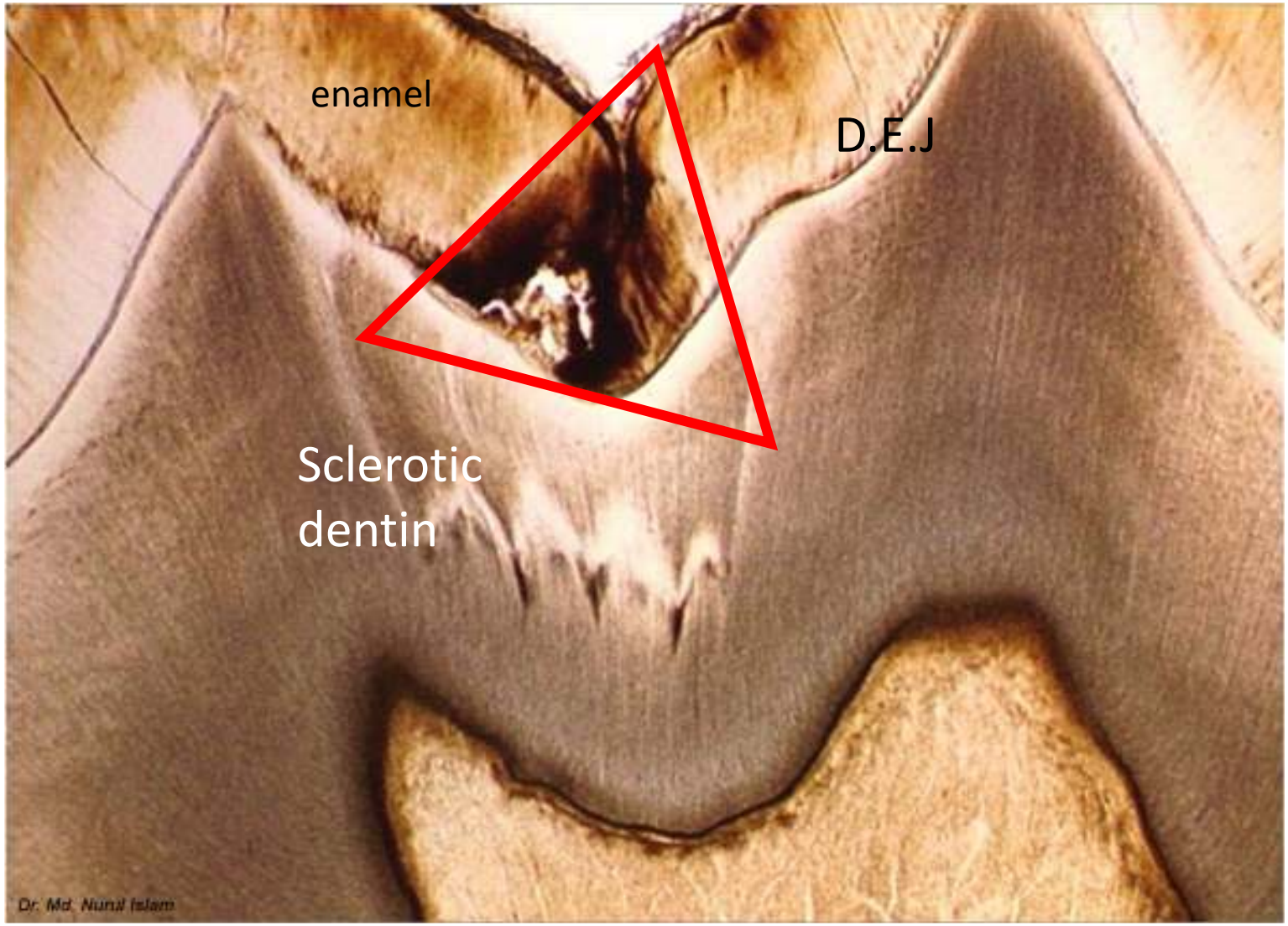
enamel
D.E.J
Sclerotic
dentin
Dr. Md. Nurul Islam

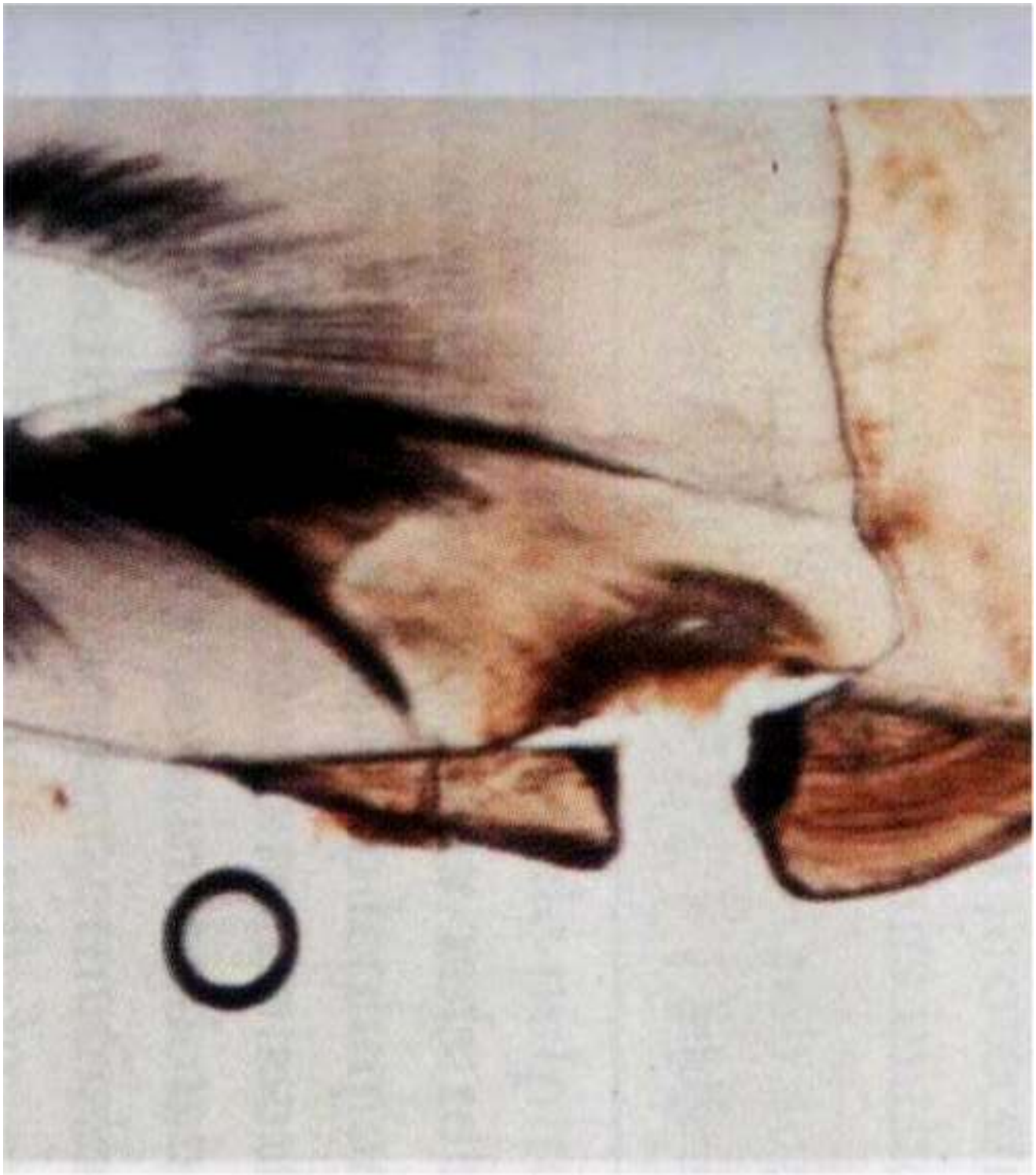

Histopathology of dentin caries

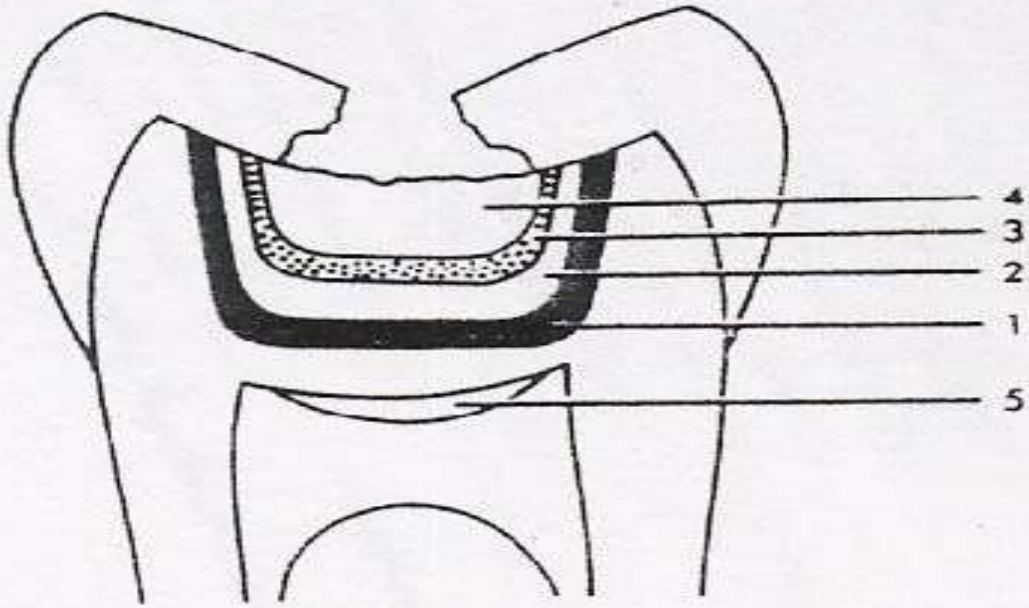

Diagrammatic representation of the zones in established dentine caries: 1. sclerosis: 2. demineralization: 3. bacterial invasion: 4. destruction: 5. reactionary. tertiary dentine beneath the lesion.

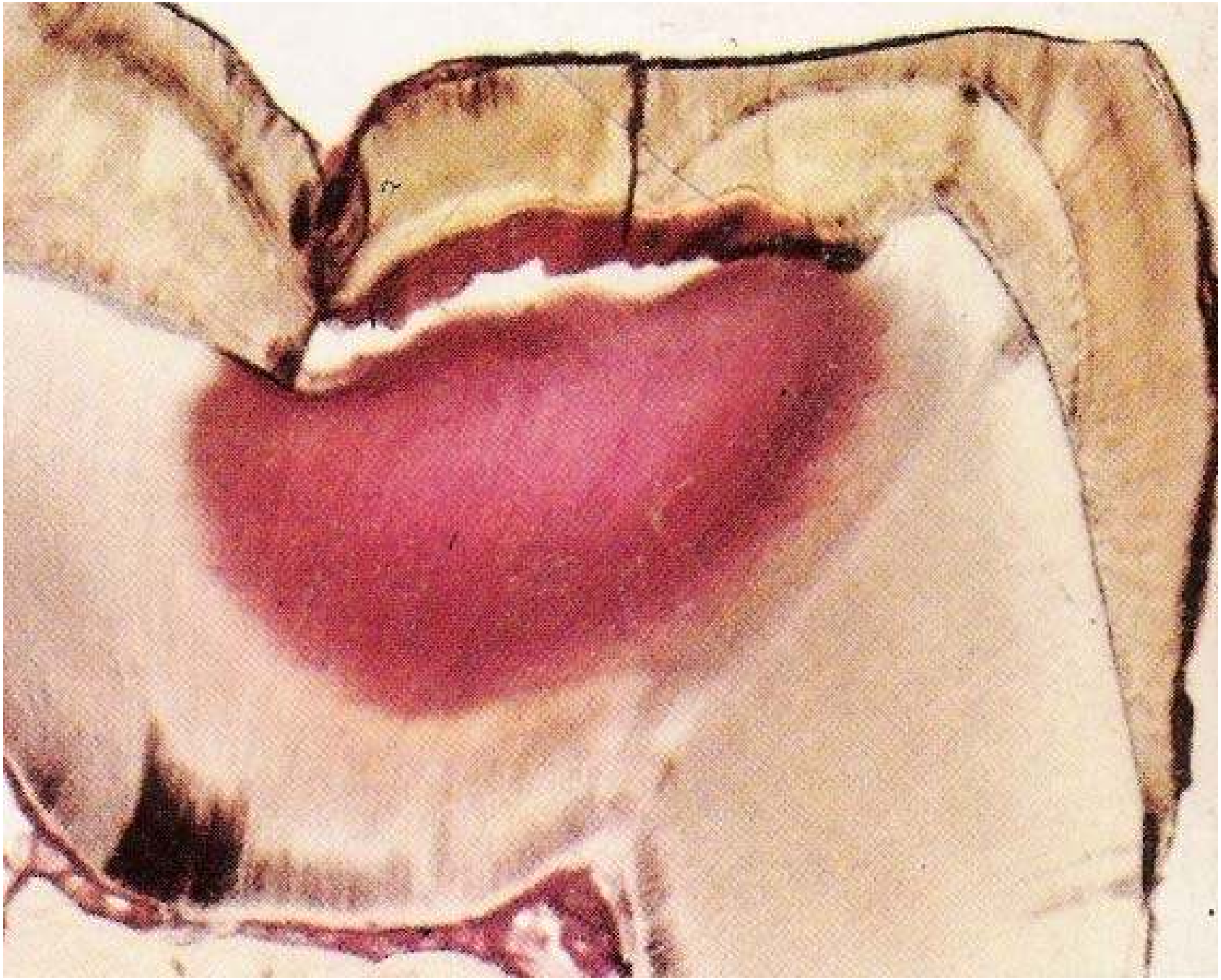

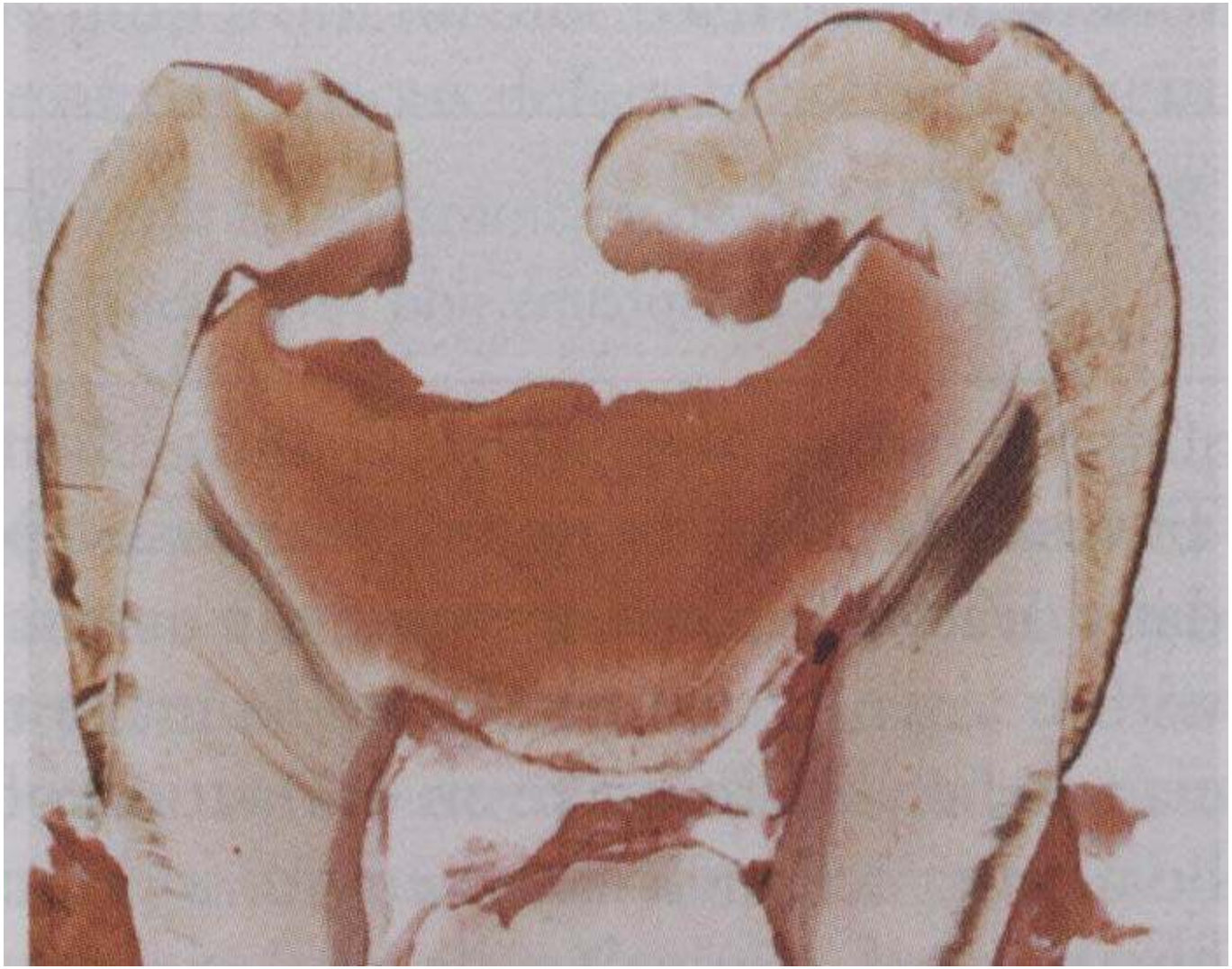

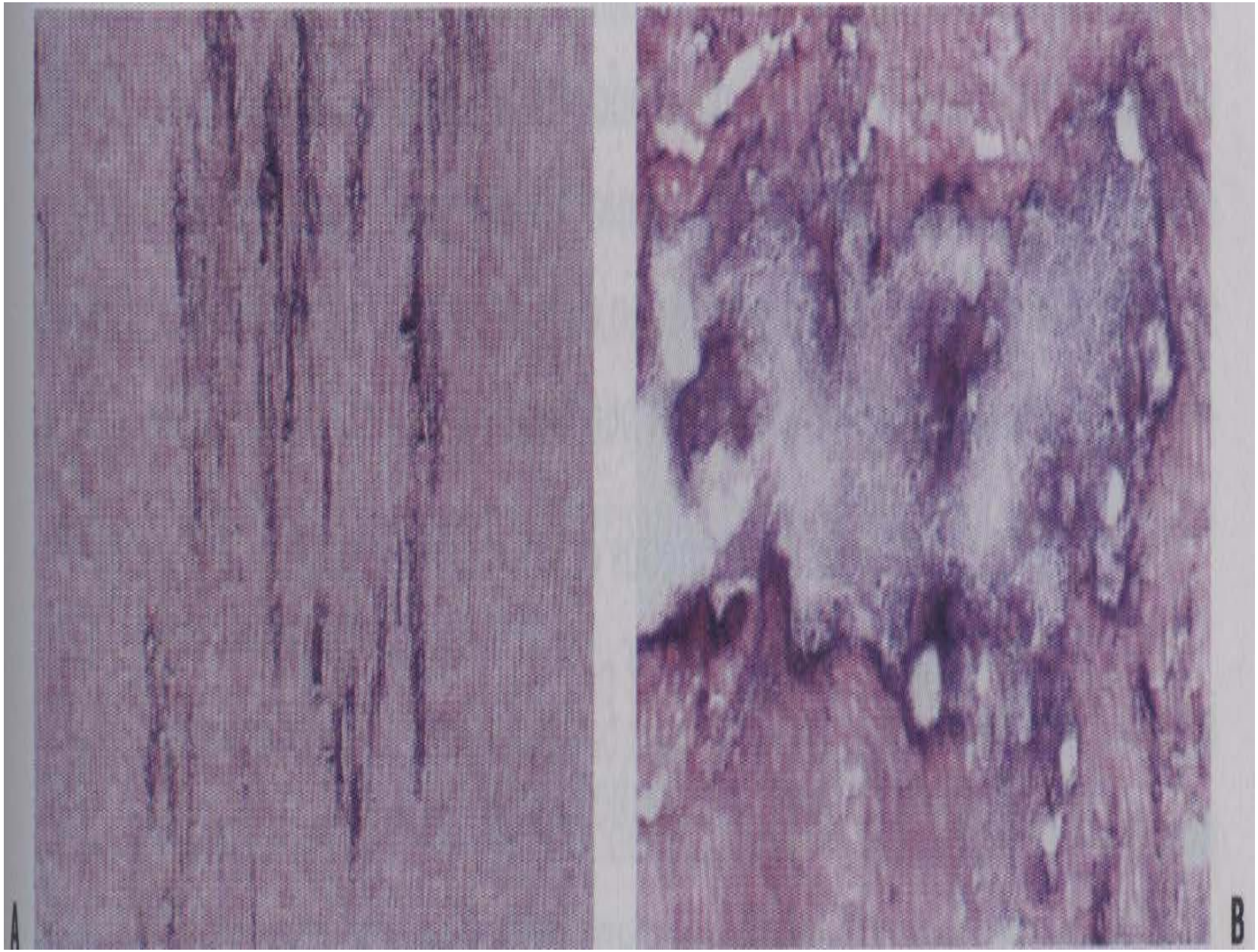
A
B

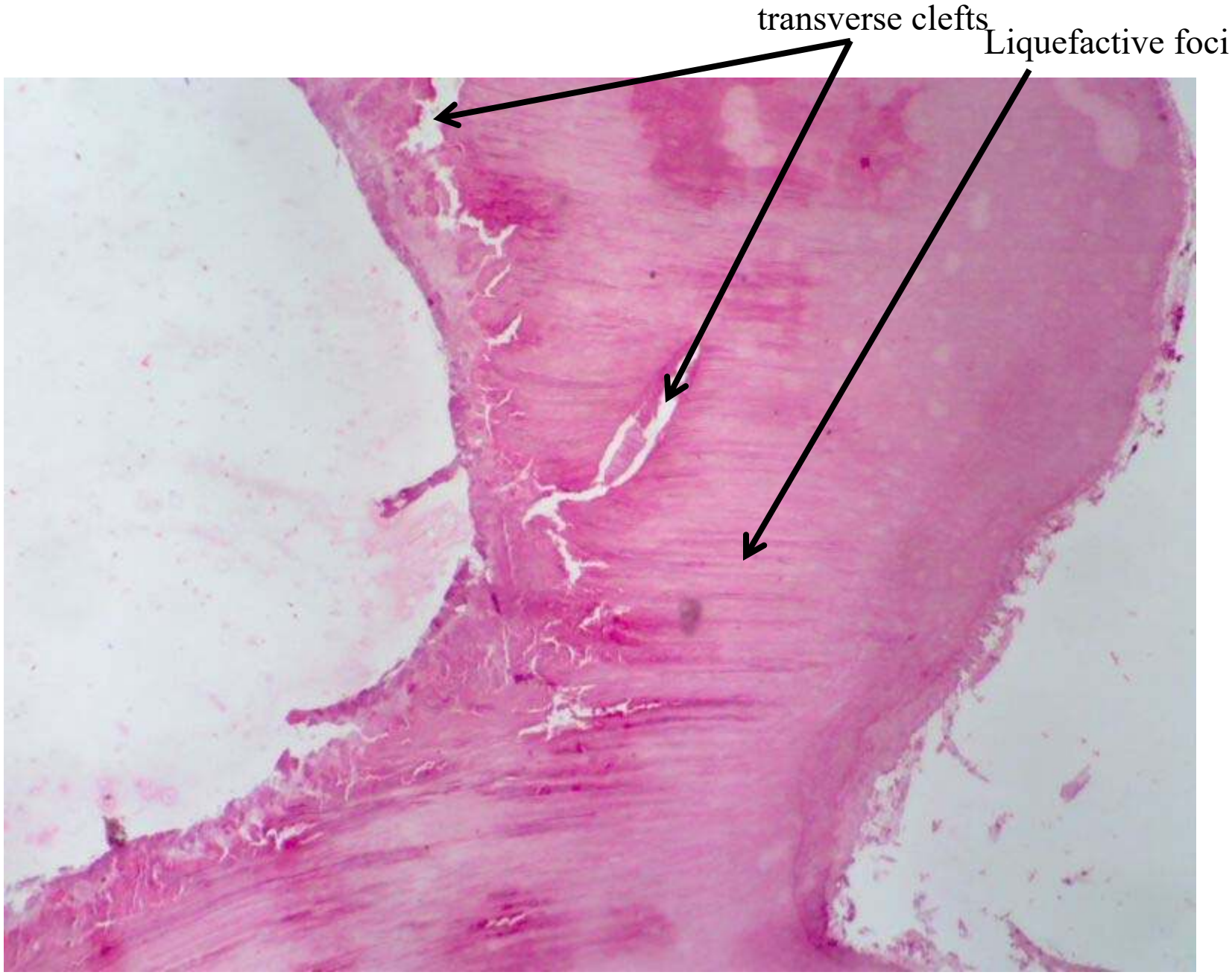

Dentin caries

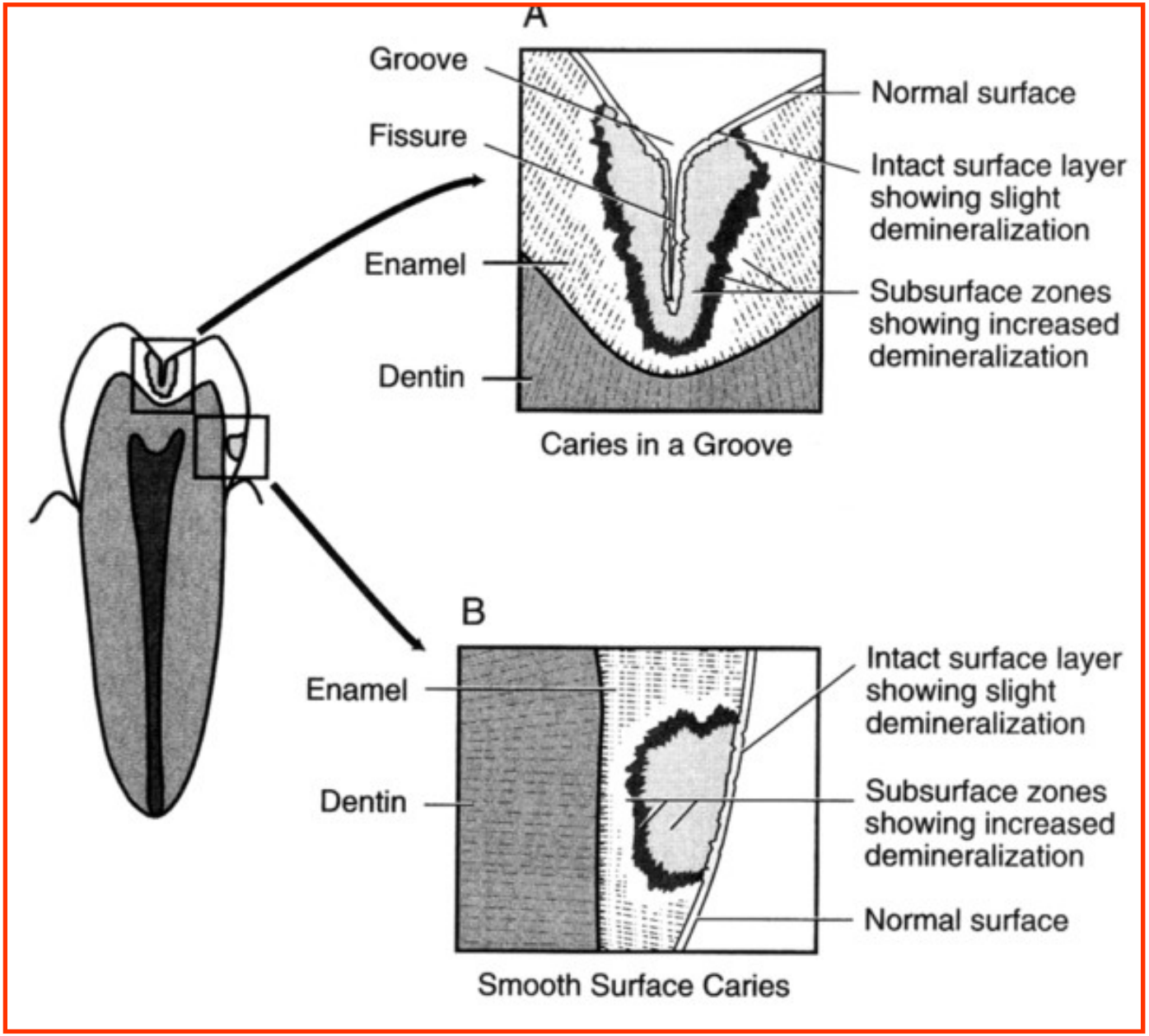
A
Groove
Fissure
Enamel
Dentin
Normal surface
Intact surface layer showing slight demineralization
Subsurface zones showing increased demineralization
Caries in a Groove
B
Enamel
Dentin
Intact surface layer showing slight demineralization
Subsurface zones showing increased demineralization
Normal surface
Smooth Surface Caries

1. A tooth surface without caries.
2. The first signs of demineralization.
3. The enamel surface has broken down.
4. A filling has been made but the demineralization has not been stopped.
5. The demineralization proceeds and undermines the tooth.
6. The tooth has fractured.

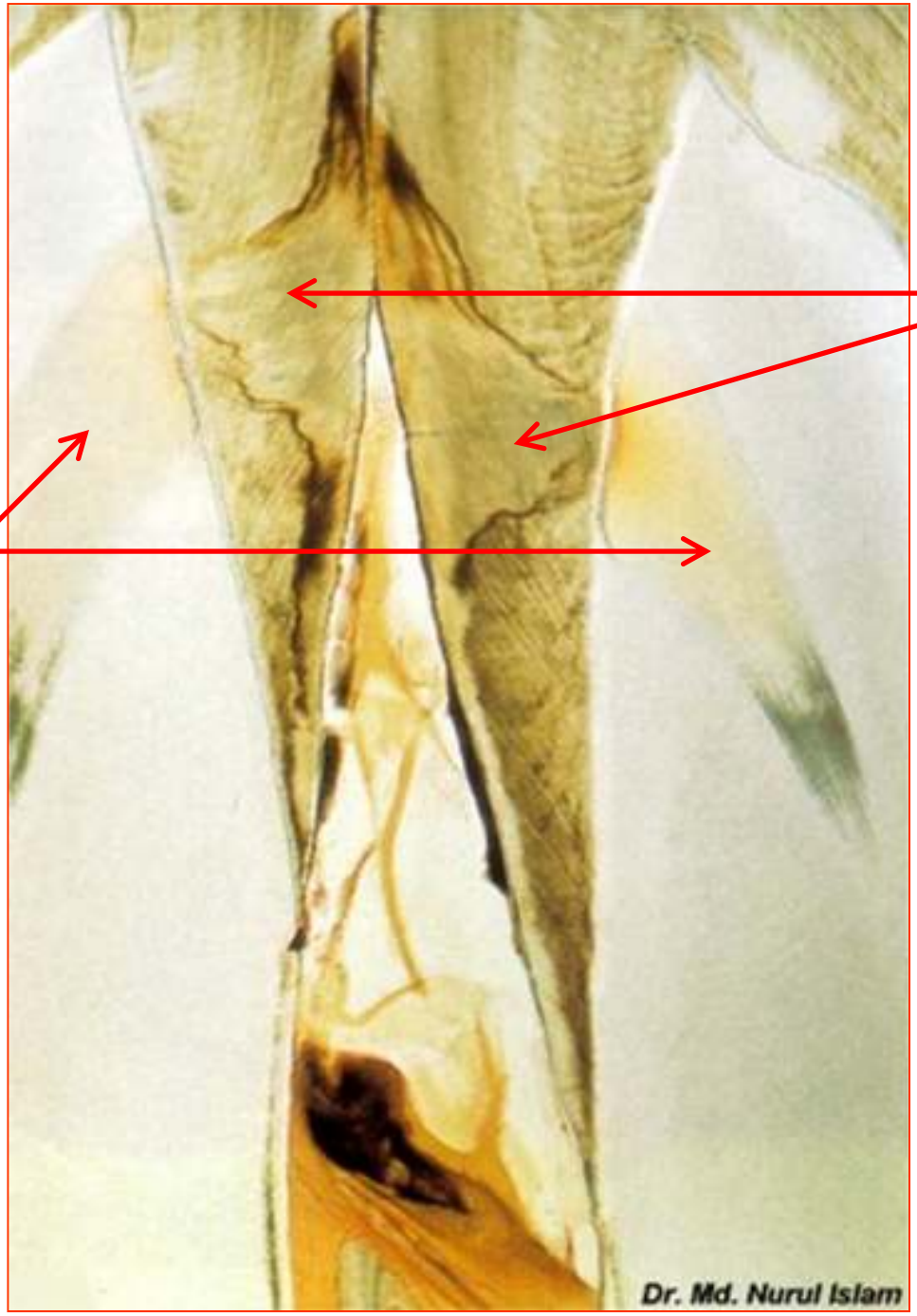

Carious lesion

Dentin reaction to caries

Enamel
caries
Sclerotic dentin
Dr. Md. Nurul Islam

Dr. Md. Nurul Islam

Dr. Md. Nurul Islam

Behind the transparent sclerotic zone, decalcification of dentin appears.

In the earliest stages, when only few tubules are involved, microorganisms may be found penetrating the tubules→ Pioneer Bacteria.

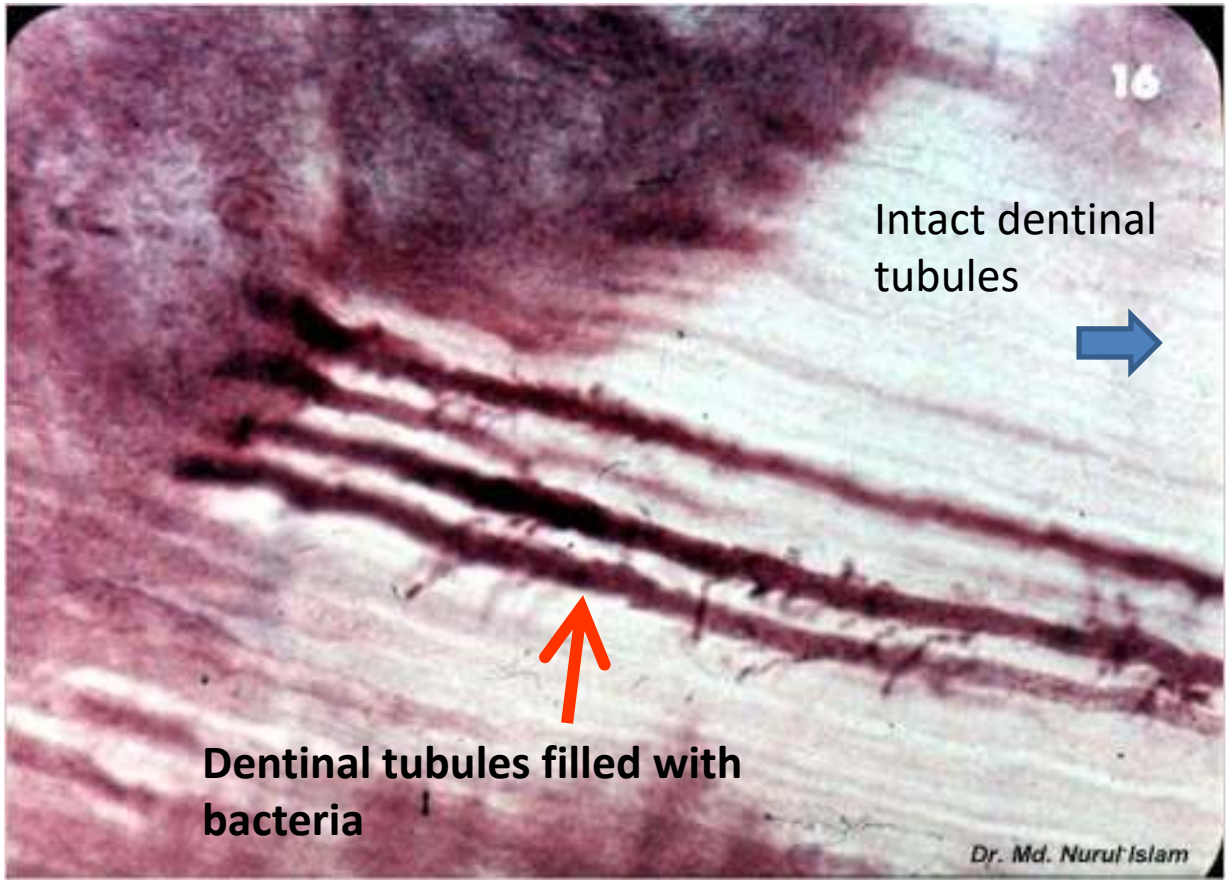

This initial decalcification involves the walls allowing them to distend as the tubules are packed with microorganisms. Each tubule is seen to be packed with pure forms of bacteria, eg., one tubule packed with coccal forms the other tubule with bacilli.

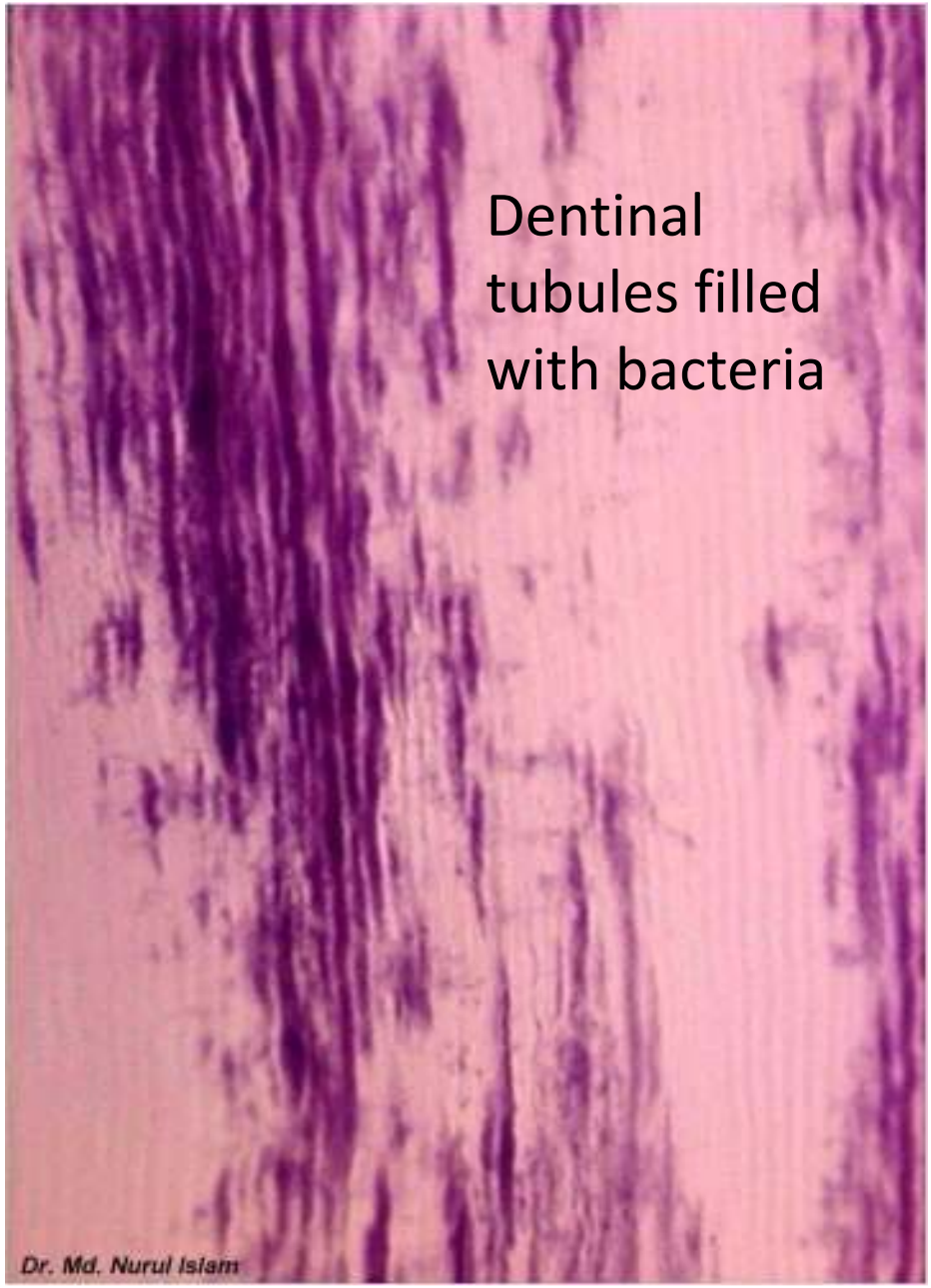

Advanced Dentinal Changes ;

-decalcification of walls, confluence of the dentinal tubules,

-tiny "liquefaction foci", described by Miller are formed by the focal coalescing and breakdown of dentinal tubules. These are ovoid areas of destruction parallel to the course of the tubules which filled with necrotic debris and increase in size by expanding. The adjacent tubules are distorted and their course is bent due to this expansion.

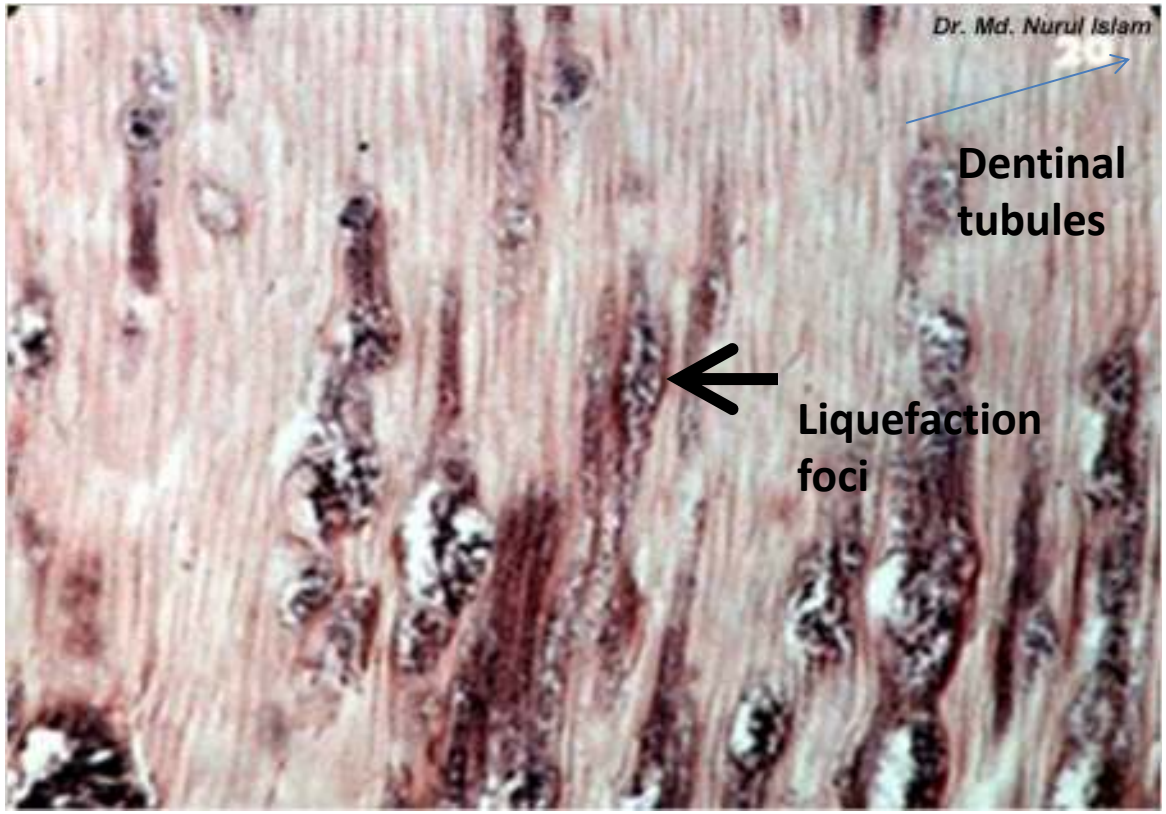

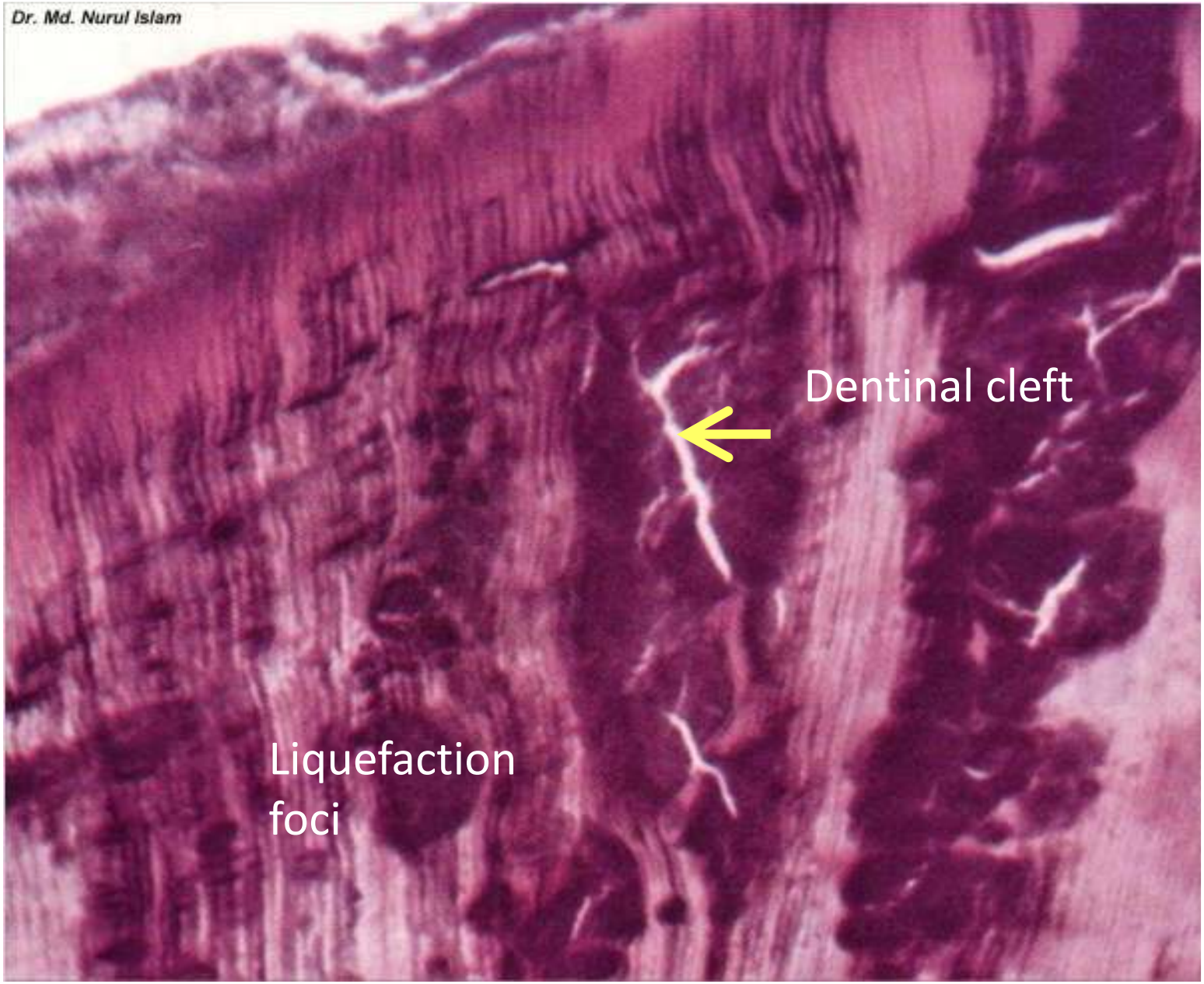
Dr. Md. Nurul Islam
Dentinal cleft
Liquefaction
foci

The destruction of dentin by decalcification and then proteolysis occurs in numerous focal areas- leading to a necrotic mass of dentin of a leathery consistency.

-clefts present in the carious dentin that extends at right angles to the dentinal tubules, accounts for the peeling off of dentin in layers while excavating.

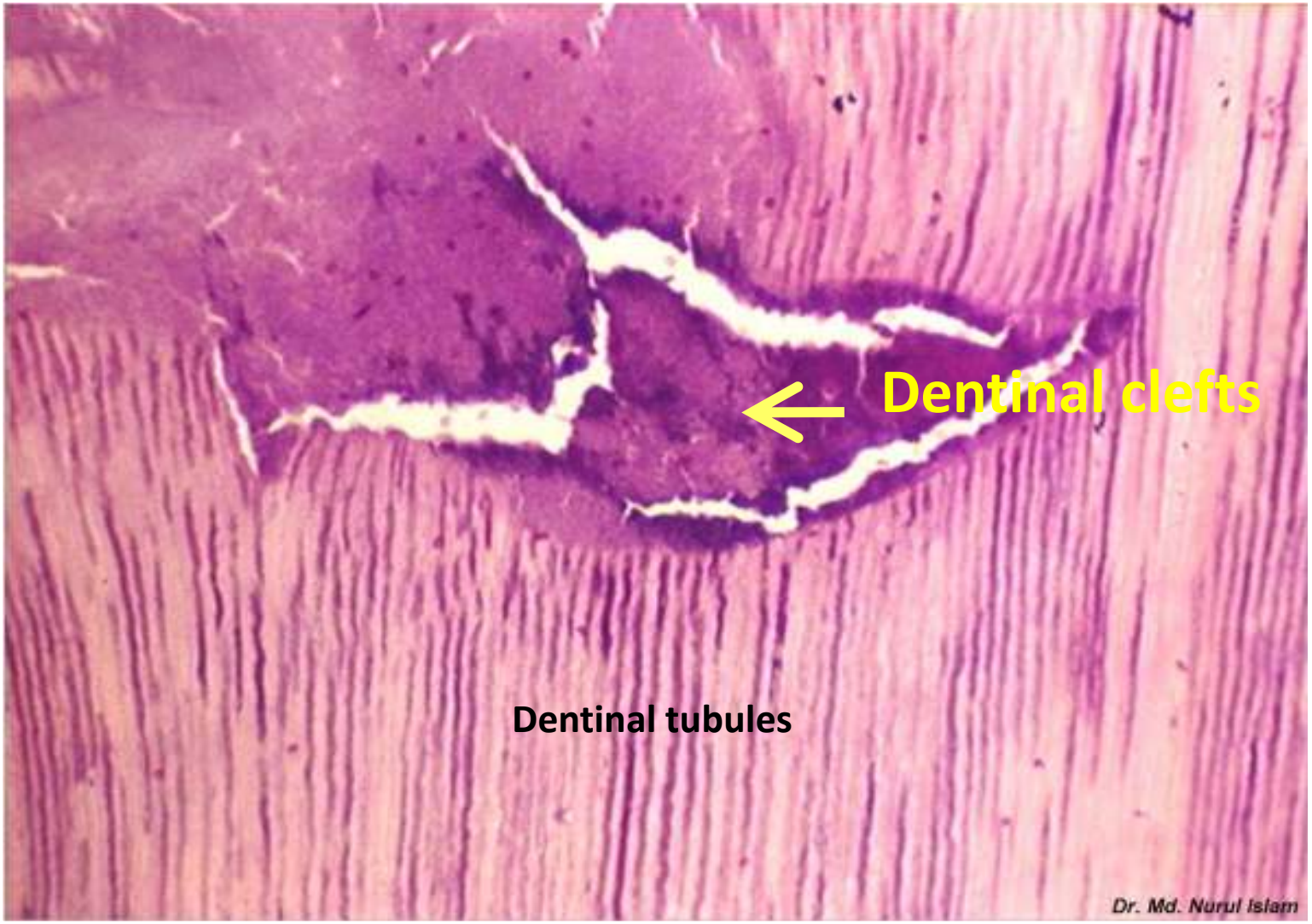
Dentinal clefts
Dentinal tubules
Dr. Md. Nurul Islam

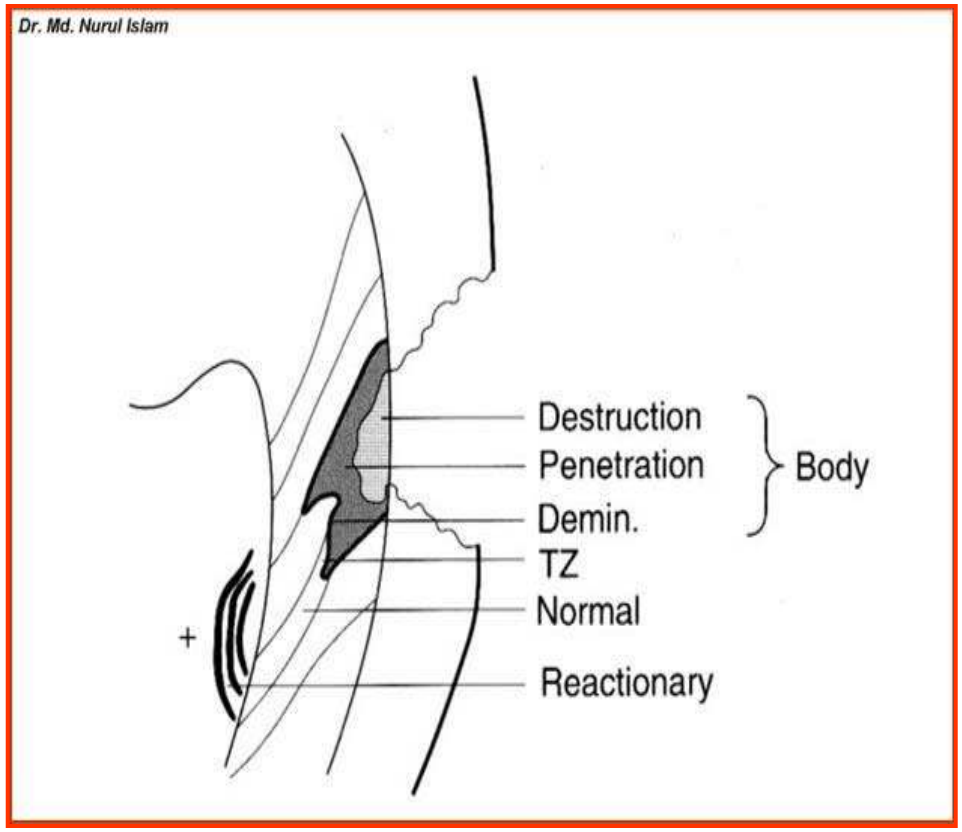
Dr. Md. Nurul Islam
Destruction
Penetration
Demin.
Body
TZ
Normal
+
Reactionary


Dr. Md. Nurul Islam